


PATIENT PRESENTING CLINICAL SIGNS

Daisy Better Life Pet Rescue

History: Whelped 6 weeks ago, is septic, constantly regurgitating.

SPECIES

Physical Examination: N/A.

Canine

Urinalysis: N/A.

BREED

CBC: N/A.

Mixed

Serum Biochemistry: N/A.

Radiographic Findings: N/A.

SEX

Intact Female

ULTRASONOGRAPHIC EXAMINATION OF THE ABDOMEN
Age

3 years

Urinary System

Full urinary bladder with a normal thickness and appearance of the wall. Small amount of floating hyperechogenic sediment present. No uroliths evident.

WEIGHT

27 #

Normal trigone area, proximal urethra, and iliac blood vessels.

Iliac lymphadenomegaly (1 x 3.9 cm) with normal shape and echogenic appearance. Ureters not visualized.

INTERPRETED BY

 Remo Lobetti, BVSc,
MMedVet (Med), PhD, Dipl.
ECVIM

Normal renal size (left 6.9 cm, right 7.3 cm), echogenic appearance, cortico-medullary differentiation, pelvis, and capsule.

Reproductive System

Normal size and appearance of the uterus (left horn 0.7 cm, right horn 0.8 cm) and ovaries (left 1.6 cm, right 1.7 cm).

IMAGING PERFORMED BY

Sonya Myers, DVM

Adrenal Glands
HOSPITAL NAME

Normal position, echogenic appearance, shape, and size. Left 0.71/0.61 cm, right 0.67/0.6 cm.

 Oviedo Veterinary Care and
Emergency

Spleen

Normal size (1.1 cm) and echogenic appearance. Smooth homogenous parenchyma, regular curvilinear capsule, and normal vasculature. No evidence of inflammatory, neoplastic, infarction, or infiltrative changes noted.

REFERRING VET

Dr Caja

Liver
INVOICE

303615

Normal size, echogenic appearance, portal markings, and regular curvilinear capsule. No nodules or masses evident. Full gall bladder containing normal anechoic bile. Normal thickness and echogenic appearance of the gall bladder wall. Normal bile duct (0.2 cm).

DATE

12/2/22


PATIENT
Gastrointestinal

Daisy Better Life Pet Rescue

SPECIES

Canine

BREED

Mixed

SEX

Intact Female

Age

3 years

WEIGHT

27 #

Normal appearance of the small intestine, ileo-cecal junction, and colon with no loss of layering, normal wall thickness (jejunum 0.39, colon 0.19 cm) and peristaltic activity, and no distension of the lumen. Fluid/ingesta/gas distended stomach and duodenum with normal thickness (duodenum 0.32 cm) and wall layering. Intussusception in the region of the ileo-cecal junction with hyperechoic irregular shadowing material (3.4 cm) in the intestinal lumen proximal to the intussusception.

Pancreas

Normal size (right 0.9 cm) and echogenic appearance. Regular capsule. Normal echogenic appearance of the mesentery and fat surrounding the pancreas.

Free Abdomen

Mesenteric lymphadenomegaly (0.7 x 1.5 cm) with normal shape and echogenic appearance. Small amount of ascites.

Thorax

Pulmonary consolidation.
No pleural effusion.

ULTRASONOGRAPHIC FINDINGS
INTERPRETED BY

Primary Findings:

- Intussusception with possible foreign body
- Lymphadenomegaly.
- Ascites.
- Pulmonary consolidation.

IMAGING PERFORMED BY

Sonya Myers, DVM

Secondary Findings:

- Urinary bladder sediment.

HOSPITAL NAME

 Oviedo Veterinary Care and
Emergency

INTERPRETATION OF THE FINDINGS & FURTHER RECOMMENDATIONS

Both the lymphadenomegaly and ascites can be ascribed to the intussusception.

Etiologies for the pulmonary consolidation would be pneumonia and atelectasis.

Further assessment would be thoracic radiographs.

Once stabilized specific therapy would be laparotomy.

REFERRING VET

Dr Caja

INVOICE

303615

DATE

12/2/22



PATIENT

Daisy Better Life Pet Rescue

SPECIES

Canine

BREED

Mixed

SEX

Intact Female

Age

3 years

WEIGHT

27 #

INTERPRETED BY

Remo Lobetti, BVSc,
 MMedVet (Med), PhD, Dipl.
 ECVIM

IMAGING PERFORMED BY

Sonya Myers, DVM

HOSPITAL NAME

Oviedo Veterinary Care and
 Emergency

REFERRING VET

Dr Caja

INVOICE

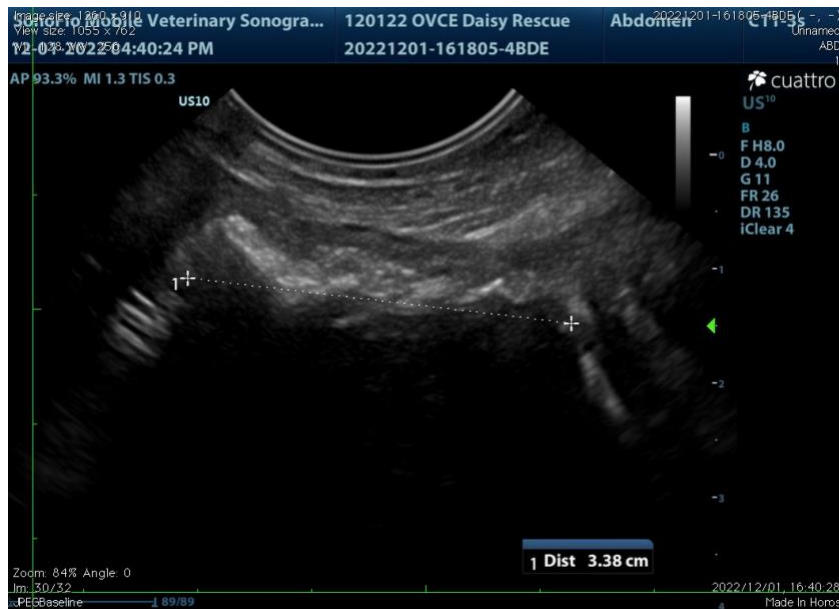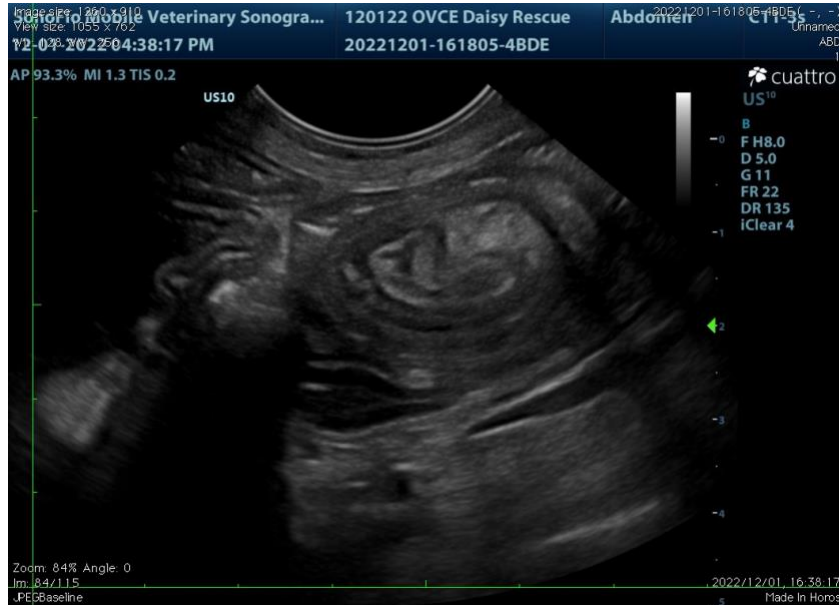303615

DATE

12/2/22

IMAGES

Small Intestine





PATIENT **Stomach**

Daisy Better Life Pet Rescue

SPECIES

Canine

BREED

Mixed

SEX

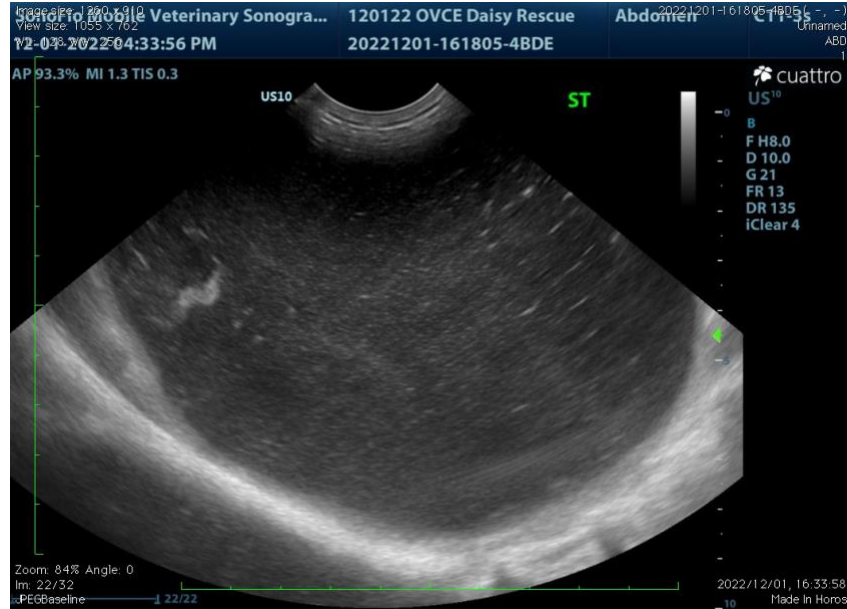
Intact Female

Age

3 years

WEIGHT

27 #



Duodenum

INTERPRETED BY

Remo Lobetti, BVSc,
 MMedVet (Med), PhD, Dipl.
 ECVIM

IMAGING PERFORMED BY

Sonya Myers, DVM

HOSPITAL NAME

Oviedo Veterinary Care and
 Emergency

REFERRING VET

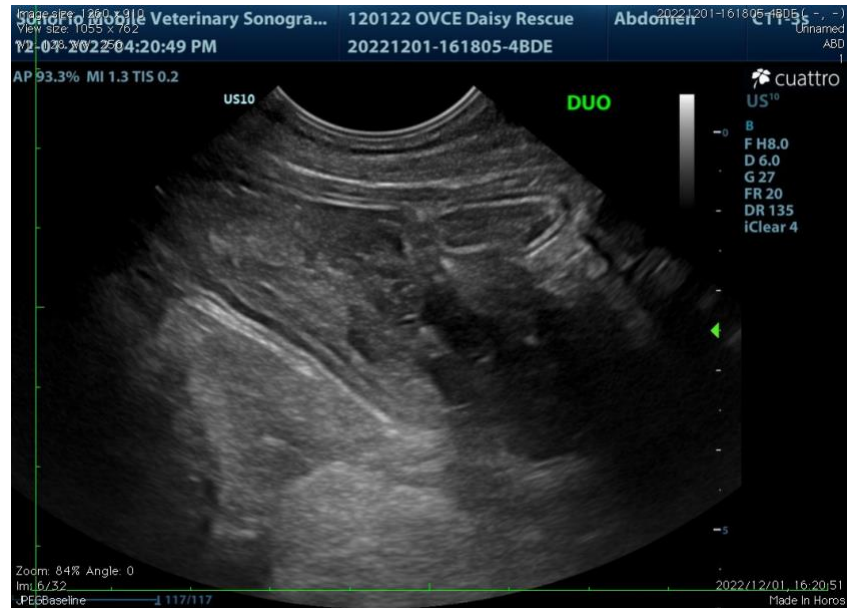Dr Caja

INVOICE

303615

DATE

12/2/22





PATIENT **Thorax**

Daisy Better Life Pet Rescue

SPECIES

Canine

BREED

Mixed

SEX

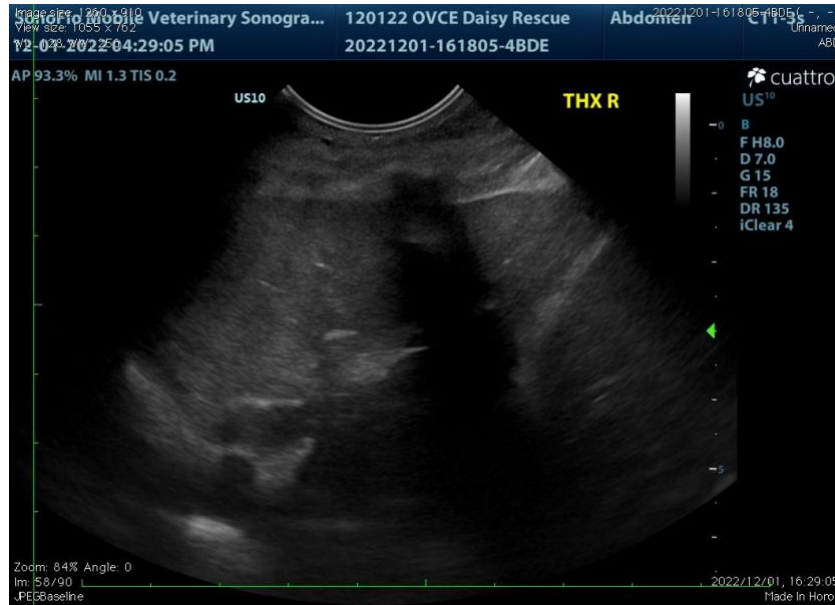
Intact Female

Age

3 years

WEIGHT

27 #



INTERPRETED BY

Remo Lobetti, BVSc,
 MMedVet (Med), PhD, Dipl.
 ECVIM

The information and recommendations provided are based on the images presented by the referring veterinarian. No evaluation can be communicated regarding pathology that was not visible in the image/video clips provided.

Thank you for this referral. If the clinical or image interpretation does not parallel your findings or if I can be of any further assistance, please contact me.

Remo Lobetti, BVSc, MMedVet (Med), PhD, Dipl. ECVIM (Internal Medicine)
rlobetti@mweb.co.za

IMAGING PERFORMED BY

Sonya Myers, DVM

HOSPITAL NAME

Oviedo Veterinary Care and
 Emergency

REFERRING VET

Dr Caja

INVOICE

303615

DATE

12/2/22